International Journal of Sport Nutrition and Exercise Metabolism, (Ahead of Print)
https://doi.org/10.1123/ijsnem.2018-0087
© 2018 Human Kinetics, Inc.

Human Kinetics
CASE STUDY

Case Study: Fatal Exertional Rhabdomyolysis Possibly Related to Drastic Weight Cutting

Kadhiresan R. Murugappan, Michael N. Cocchi, Somnath Bose, Sara E. Neves, Charles H. Cook, Todd Sarge, Shahzad Shaefi, and Akiva Leibowitz
Beth Israel Deaconess Medical Center (BIDMC)

Rapid weight loss or "weight cutting" is a dangerous practice that is ubiquitous in modern combat sports yet underrepresented in the medical literature. We present a case of exertional rhabdomyolysis in a mixed martial artist with sickle cell trait to illustrate the hazards of weight cutting and ensuing critical illness. Sickle cell trait is known to predispose patients to exertional rhabdomyolysis, and multiple fatal cases have been reported in the setting of strenuous exercise. Dehydration and consequent electrolyte abnormalities make combat sport athletes with sickle cell trait particularly vulnerable to this entity. This case suggests a potential role for sickle cell trait screening in this population and underscores the need for safer weight-control practices and monitoring among all combat sport athletes.

Keywords: acute respiratory distress syndrome, body composition, disseminated intravascular coagulation, martial arts, metabolism, muscle function, sickle cell trait

Rapid weight loss or "weight cutting" has become commonplace among athletes competing in wrestling, boxing, and martial arts. Mixed martial artists, like other combat sport athletes, are required to adhere to strict weight classifications designed to promote fair play among competitors. Intent notwithstanding, athletes typically seek to compete at the lowest possible weight division to gain a perceived competitive advantage over potentially smaller opponents. To achieve this end, combatants engage in rapid weight-loss methods involving significant dehydration in a pervasive practice known as "weight cutting."

Common strategies used to "cut" weight include fluid and food restriction, prolonged sauna sessions, hot baths, diuretics, and exercise in vapor-impermeable suits to induce sweating. Competitors have been shown to lose 10% or more of their body weight in the week preceding competition and an additional 5% the day prior to the weigh-in (Crighton et al., 2016). Despite attempts at rehydration, Jetton et al. (2013) found that only 23% of mixed martial artists were well hydrated before competition. Furthermore, up to 80% of combat sports athletes may be significantly dehydrated on the day of their bout (Pettersson & Berg, 2014). We present a case that illustrates the potential complications of this practice.

Case Report

The Institutional Review Board waived the requirement for informed consent; however, written informed consent from the patient's health care proxy was obtained for the publication of this report. A previously healthy 26-year-old African American male with sickle cell trait presented to a local emergency department immediately after an amateur mixed martial arts bout. The patient had a witnessed collapse due to exhaustion in the final round of a grueling three-round bout. During the match, observers noted that the patient received minimal physical damage and that the fall was not related to any particular strike. The bout was stopped to protect the patient who was not defending himself effectively.

The patient had undergone an intentional weight cut of 5 kg the day prior to competition, facilitated by the use of prolonged time in a sauna and hot tub. Vital signs on initial presentation were notable for severe tachypnea (55 breaths/min). Physical examination demonstrated a muscular African American male who was initially unresponsive but quickly became more alert and restless.

Electrocardiogram was suggestive of hyperkalemia, and empiric treatment was administered, including intravenous dextrose, insulin, and sodium bicarbonate. The basic metabolic panel was remarkable for hypernatremia (148 mEq/L, reference range 133–145), hyperkalemia (5.6 mEq/L, reference range 3.3–5.1), acidemia with serum bicarbonate of 8 mEq/L (reference range 22–32), and acute kidney injury with a serum creatinine of 1.98 mg/dl (reference range 0.5–1.2). Imaging studies including computed tomography scans of the head, cervical spine, chest, abdomen, and pelvis were unrevealing. A urine toxicology screen was negative.

The patient was then transferred to our tertiary care trauma center for further care, where he began to complain of diffuse myalgias. Notable laboratory studies upon transfer included serum potassium of 9.9 mEq/L, lactic acid of 19.9 mmol/L (reference range 0.5–2.0), and serum creatinine of 2.5 mg/dl. Creatine kinase (CK) was elevated at 2,271 IU/L (reference range 29–201) and increased precipitously to 17,500 IU/L within 2 hr (Figure 1).

Despite aggressive fluid resuscitation, he progressed to anuria. Emergent hemodialysis was initiated for recalcitrant hyperkalemia and acidosis upon arrival to the trauma intensive care unit. Profound hemodynamic instability and respiratory failure necessitated vasopressor support and mechanical ventilation.

Murugappan, Cocchi, Bose, Neves, Sarge, Shaefi, and Leibowitz are with the Dept. of Anesthesia, Critical Care, and Pain Medicine, Beth Israel Deaconess Medical Center (BIDMC), Boston, MA. Cocchi is also with the Dept. of Emergency Medicine, BIDMC, Boston, MA. Cook is with the Dept. of Acute Care Surgery, Trauma, and Surgical Critical Care, BIDMC, Boston, MA. Address author correspondence to Kadhiresan R. Murugappan at kmurugap@bidmc.harvard.edu.

On hospital Day 2, transthoracic echocardiography demonstrated preserved biventricular function. Potassium improved to 6.7 mEq/L, and the patient was transitioned to continuous renal replacement therapy for management of ongoing hyperkalemia and oliguric renal failure in the setting of hemodynamic instability and multipressor shock. Empiric antibiotics and hydrocortisone were administered. The patient was diagnosed with severe exertional rhabdomyolysis with pigment-induced renal failure likely related to profound volume depletion. Despite the maximal supportive therapy, serum CK and potassium progressively worsened (Figure 1).

Later that day, physical examination demonstrated significant swelling of the bilateral lower extremities. Bilateral fasciotomies of the patient's calves and thighs were performed at bedside due to concern for evolving compartment syndrome. As his course progressed, the patient developed bloody stool and elevated bladder pressures. He underwent a bedside exploratory laparotomy that was unremarkable. Following the procedure, the patient began to bleed profusely from his fasciotomy and abdominal wounds, prompting suspicion for disseminated intravascular coagulation in addition to the coagulopathic effects of refractory hypothermia present throughout his hospital course. Serum hemoglobin dropped from 11–6.3 g/dl (reference range 11.2–15.7) and fibrinogen was 55 mg/dl (reference range 180–400).

A massive transfusion protocol was initiated, culminating in 33 units of packed red blood cells, 24 units of fresh frozen plasma, 10 units of cryoprecipitate, and 5 six-pack units of pooled platelets. CK continued to rise to 222,100 IU/L. Serum alanine aminotransferase and aspartate aminotransferase were elevated, consistent with "shock liver (ischemic hepatitis)."

On hospital Day 3, the patient developed severe acute respiratory distress syndrome (Figure 2) with a ratio of the partial pressure of arterial oxygen (PaO_2, in mmHg) to the fraction of inspired oxygen (FiO_2) as low as 54. After the addition of neuromuscular

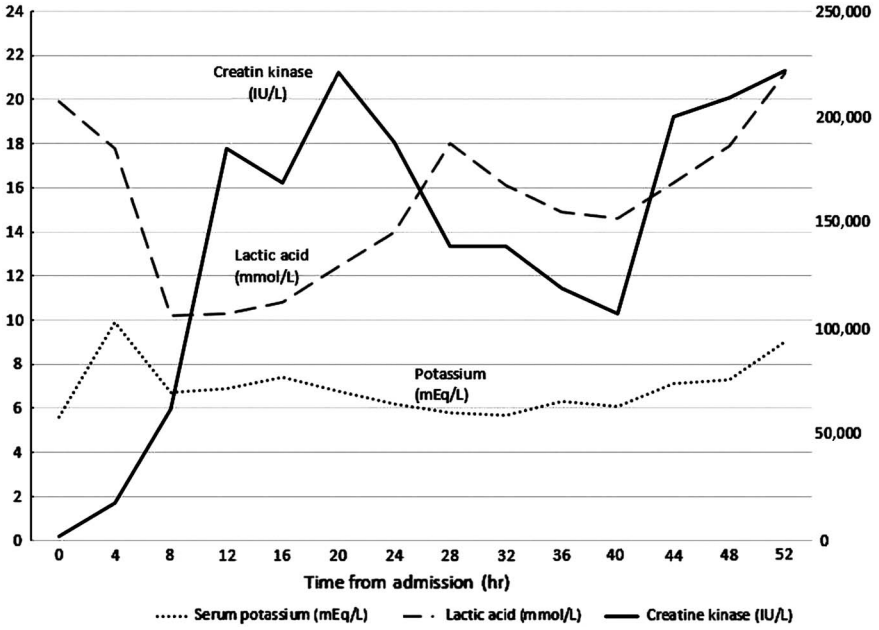

Figure 1 — Trends of serum potassium, lactic acid, and CK throughout hospitalization, reflecting the profound, refractory metabolic derangements. CK indicates creatine kinase.

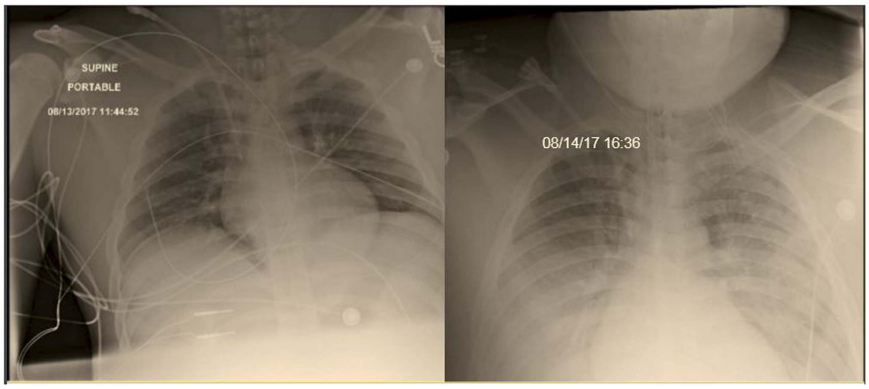

Figure 2 — Chest radiograph from hospital Day 2 demonstrating clear lung fields (left panel). Comparison film from hospital Day 3 revealing pulmonary vascular congestion and bilateral opacities consistent with acute respiratory distress syndrome (right panel).

Downloaded by t_lambrinides@yahoo.com on 09/18/18, Volume ${article.issue.volume}, Article Number ${article.issue.issue}

Downloaded by t_lambrinides@yahoo.com on 09/18/18, Volume ${article.issue.volume}, Article Number ${article.issue.issue}

blockade, inhaled nitric oxide and positive end-expiratory pressure titration guided by esophageal balloon improved the patient's oxygenation. Over the course of a few hours, aided by gentle fluid removal, the patient's PaO_2:FiO_2 ratio increased to 245. He continued to bleed profusely and was supported with transfusions as well as vasopressor support with epinephrine, phenylephrine, norepinephrine, and vasopressin. Methylene blue was administered for refractory vasoplegia.

A portable head computed tomography scan revealed cerebral edema, and repeat transthoracic echocardiography demonstrated moderately depressed left ventricular function and volume overload. While the patient was profoundly hypoxemic and hypercarbic, he was considered for veno-venous extracorporeal membrane oxygenation but deemed not a candidate due to bleeding diathesis and improvement in oxygenation with lung recruitment and positive end-expiratory pressure optimization. While on continuous renal replacement therapy, the patient's serum CK continued to climb, peaking at 223,100 IU/L.

Later that evening, despite maximal continuous renal replacement therapy, the serum potassium rose to 9.1 mEq/L. The patient was noted to have intermittent bouts of bradycardia that initially responded to medical treatment, but soon progressed to asystolic cardiac arrest. Despite ongoing resuscitative efforts, including maximal medical treatment for hyperkalemia in addition to continuous renal replacement therapy, in the setting of maximal vasopressors, worsening acidosis, and coagulopathy, the patient expired.

Discussion

Sickle cell trait is known to predispose patients to exertional rhabdomyolysis, and multiple fatal cases have been reported in the setting of strenuous exercise (Connes, 2015; Dincer & Raza, 2005; Eichner, 2010; Gardner & Kark, 1994; Harris et al., 2012). Among affected National Collegiate Athletic Association (NCAA) Division I football players, the risk of exertional death was 37 times higher than in athletes without sickle cell trait (Harmon et al., 2012). The pathophysiologic mechanism remains unclear; however, increased sickling of erythrocytes occurring during physical exercise has been demonstrated in vivo in affected individuals (Martin et al., 1989).

Three prior deaths due to exertional sickling in combat sports competition have been reported. Walker Atrice, 30, died during a Golden Gloves boxing competition in 2008. Atrice was noted to have had "stamina problems" in prior amateur boxing matches despite daily training and work as a boxing coach and trainer. He collapsed after a strong start. His bout was stopped in the third round, and attempts at resuscitation were unsuccessful. George Clinkscale, 24, died after his debut in an unsanctioned amateur boxing match in 2011. The autopsy report listed sudden exertional death due to complications of sickle cell trait as the cause of death. Kickboxer Dennis Munson Jr., 24, also died in his debut. He similarly began the fight strong before appearing fatigued in the second round, with notable gait disturbances. He collapsed after the final bell in the third round and died shortly after transport to a local hospital. Though blunt force injuries of the head were officially listed as the cause of death, lab analysis suggested that he suffered from rhabdomyolysis, and all evaluated tissue slides revealed sickled red blood cells corresponding to the patient's known history of sickle cell trait. Evaluation of the head was unremarkable and revealed no evidence of scalp hematoma or skull fracture and no signs of epidural, subdural, or subarachnoid bleeding. The report also notes that the decedent engaged in a restricted diet for a period of weeks to months before the event. An additional reported death is that of A.J. Jewell, whose cause of death was listed as sickle cell trait–related exertional collapse following a street fight.

Although exertional sickling can occur in the absence of prior dehydration or weight cutting, dehydration has been linked to adverse effects during exercise in patients with sickle cell trait (Anzalone et al., 2010; Eisenbach et al., 2005; Kark et al., 1987). Our patient's weight prior to his first bout was 104.3 kg (230 lbs). He cut down to 77.1 kg (170 lbs) over a period of 3 months, losing the large majority of the weight in the week prior to weigh-in. This amounts to a total of 26.1% of his body mass lost. His weight management was conducted under the guidance of a nutritionist who prepared his meals daily. In addition to fluid and food restriction, our patient was known to use sauna sessions to cut weight. Such methods are common practice among combat sports athletes (Reale et al., 2017). Following weigh-in, he attempted rehydration with water, commercial sports drinks, and a carbohydrate-rich diet consisting largely of pasta.

After winning his first match, our patient had difficulty in rehydrating and noted feeling ill. As a result, he had to cut only 5 kg (11 lbs) for his second and final bout 6 weeks later, all of which he lost in a sauna session within 24 hr of weigh-in. Given these circumstances, our patient was likely significantly dehydrated before his bout. We believe dehydration associated with rapid weight loss in this patient with sickle cell trait set the stage for exertional rhabdomyolysis, leading to acute renal failure and refractory hyperkalemia. He suffered other known consequences of rhabdomyolysis, including compartment syndrome and disseminated intravascular coagulation as well as severe acute respiratory distress syndrome likely resulting from a combination of capillary leak, volume overload, and massive transfusion (Huerta-Alardin et al., 2005; Ward, 1988).

The patient's experience suggests a potential role for sickle cell trait screening in combat sports as the NCAA and certain branches of the military have adopted (Bonham et al., 2010; Nelson et al., 2016). With regard to the former group, the policy has faced scrutiny due to potential stigmatization and a low absolute risk among all NCAA athletes despite a high relative risk of exertional death in patients with sickle cell trait (Thompson, 2013). We argue that combat sports athletes represent a more vulnerable population due to dehydration and electrolyte disturbances related to weight cutting, and therefore they would more likely benefit from screening.

We estimate more than 100,000 individual weigh-ins occur annually among combat sports athletes (BoxRec, 2017; Palmquist, 2017). While underrepresented in published medical literature, several cases of morbidity and mortality related to weight cutting have been reported in lay media. Importantly, these cases highlight that the dangers of weight cutting extend beyond athletes with sickle cell trait.

Sports nutritionists should be familiar with the dangers of severe dehydration in combat sports athletes. Those working with athletes cutting weight should regularly assess weight and hydration status and encourage long-term weight-loss methods that avoid extreme hypohydration. Avoiding dehydration entirely is likely not realistic, given the pervasive culture of weight cutting in combat sports. In a recent review on the subject, Reale et al. recommend consumption of strategic amounts of low weight/low fiber foods while inducing a mild fluid deficit to achieve weight loss no greater than 8% body mass for safety and to preserve performance. They suggest that this limit should be reduced further to 5% in athletes with shorter recovery times before competition (Reale et al., 2017). Professionals working with these athletes should have an understanding of strategies used for rapid weight loss, the specific weight procedures applicable to a particular competition, and the consequences of acute and chronic dehydration that could potentially result.

Clinicians encountering athletes after weight cuts should be cognizant of complications of dehydration and strenuous exercise, including rhabdomyolysis. When the diagnosis is suspected, vigilant monitoring of renal function, electrolyte levels, and telemetry is prudent. Genetic mutations should also be considered in the differential diagnosis for exertional rhabdomyolysis. Multiple defects have been implicated, including those of lipid metabolism and the RYR1 gene, which has been linked with malignant hyperthermia (Cucchiari et al., 2018; Riazi et al., 2018).

In conclusion, this case illustrates the dangers of rapid weight loss and the challenges in management of severe exertional rhabdomyolysis leading to multiorgan failure. In response to other fatal cases among combat sports athletes, the California State Athletic Commission recently adopted regulations to reform weight-cutting policies. Further studies of such measures are warranted. It is our hope that similar strategies and greater awareness can help to prevent other potentially avoidable tragedies.

Acknowledgments

The manuscript was prepared by K. R. Murugappan, M. N. Cocchi, S. Bose, S. E. Neves, C. H. Cook, T. Sarge, S. Shaefi, and A. Leibowitz. All authors approved the final version of the manuscript. The authors wish to thank Andy Foster, Executive Director of the California State Athletic Commission, for his support for the project and data contribution. No financial support was used for the production of this manuscript, and the authors have no relevant conflicts of interest. All work was performed at BIDMC.

References

Anzalone, M.L., Green, V.S., Buja, M., Sanchez, L.A., Harrykissoon, R.I., & Eichner, E.R. (2010). Sickle cell trait and fatal rhabdomyolysis in football training: A case study. *Medicine & Science in Sports & Exercise, 42*(1), 3–7. PubMed ID: 20010136 doi:10.1249/MSS.0b013e3181ae0700

Bonham, V.L., Dover, G.J., & Brody, L.C. (2010). Screening student athletes for sickle cell trait—a social and clinical experiment. *The New England Journal of Medicine, 363*(11), 997–999. PubMed ID: 20825310 doi:10.1056/NEJMp1007639

BoxRec. (2017). Boxing records archive. Retrieved from www.boxrec.com

Connes, P. (2015). Sickle cell trait, exertional rhabdomyolysis, and compartment syndrome. *The Lancet, 385*(9981), 1948. PubMed ID: 26090643 doi:10.1016/S0140-6736(15)60961-8

Crighton, B., Close, G.L., & Morton, J.P. (2016). Alarming weight cutting behaviours in mixed martial arts: A cause for concern and a call for action. *British Journal of Sports Medicine, 50*(8), 446–447. PubMed ID: 26459278 doi:10.1136/bjsports-2015-094732

Cucchiari, D., Colombo, I., Amato, O., Podesta, M.A., Reggiani, F., Valentino, R., . . . Badalamenti, S. (2018). Exertional rhabdomyolysis leading to acute kidney injury: When genetic defects are diagnosed in adult life. *CEN Case Reports, 7*(1):62–65. PubMed ID: 29234986 doi:10.1007/s13730-017-0292-z

Dincer, H.E., & Raza, T. (2005). Compartment syndrome and fatal rhabdomyolysis in sickle cell trait. *WMJ: Official Publication of the State Medical Society of Wisconsin, 104*(6), 67–71. PubMed ID: 16218320

Eichner, E.R. (2010). Sickle cell trait in sports. *Current Sports Medicine Reports, 9*(6), 347–351. PubMed ID: 21068567 doi:10.1249/JSR.0b013e3181fc73d7

Eisenbach, C., Pohl, J., Dikow, R., Stremmel, W., & Encke, J. (2005). Severe rhabdomyolysis and renal failure triggered by a sauna visit in sickle cell trait: A case report. *Clinical Nephrology, 63*(3), 229–231. PubMed ID: 15786826 doi:10.5414/CNP63229

Gardner, J.W., & Kark, J.A. (1994). Fatal rhabdomyolysis presenting as mild heat illness in military training. *Military Medicine, 159*(2), 160–163. PubMed ID: 8202248 doi:10.1093/milmed/159.2.160

Harmon, K.G., Drezner, J.A., Klossner, D., & Asif, I.M. (2012). Sickle cell trait associated with a RR of death of 37 times in National Collegiate Athletic Association football athletes: A database with 2 million athlete-years as the denominator. *British Journal of Sports Medicine, 46*(5), 325–330. PubMed ID: 22442191 doi:10.1136/bjsports-2011-090896

Harris, K.M., Haas, T.S., Eichner, E.R., & Maron, B.J. (2012). Sickle cell trait associated with sudden death in competitive athletes. *The American Journal of Cardiology, 110*(8), 1185–1188. PubMed ID: 22809753 doi:10.1016/j.amjcard.2012.06.004

Huerta-Alardin, A.L., Varon, J., & Marik, P.E. (2005). Bench-to-bedside review: Rhabdomyolysis—an overview for clinicians. *Critical Care, 9*(2), 158–169. PubMed ID: 15774072 doi:10.1186/cc2978

Jetton, A.M., Lawrence, M.M., Meucci, M., Haines, T.L., Collier, S.R., Morris, D.M., & Utter, A.C. (2013). Dehydration and acute weight gain in mixed martial arts fighters before competition. *Journal of Strength & Conditioning Research, 27*(5), 1322–1326. PubMed ID: 23439336 doi:10.1519/JSC.0b013e31828a1e91

Kark, J.A., Posey, D.M., Schumacher, H.R., & Ruehle, C.J. (1987). Sickle-cell trait as a risk factor for sudden death in physical training. *The New England Journal of Medicine, 317*(13), 781–787. PubMed ID: 3627196 doi:10.1056/NEJM198709243171301

Martin, T.W., Weisman, I.M., Zeballos, R.J., & Stephenson, S.R. (1989). Exercise and hypoxia increase sickling in venous blood from an exercising limb in individuals with sickle cell trait. *The American Journal of Medicine, 87*(1), 48–56. PubMed ID: 2741981 doi:10.1016/S0002-9343(89)80482-6

Nelson, D.A., Deuster, P.A., Carter, R., 3rd, Hill, O.T., Wolcott, V.L., & Kurina, L.M. (2016). Sickle cell trait, rhabdomyolysis, and mortality among U.S. army soldiers. *The New England Journal of Medicine, 375*(5), 435–442. PubMed ID: 27518662 doi:10.1056/NEJMoa1516257

Palmquist, C. (2017). Retrieved from http://www.mixedmartialarts.com/events/results

Pettersson, S., & Berg, C.M. (2014). Hydration status in elite wrestlers, judokas, boxers, and taekwondo athletes on competition day. *International Journal of Sport Nutrition and Exercise Metabolism, 24*(3), 267–275. PubMed ID: 24280038 doi:10.1123/ijsnem.2013-0100

Reale, R., Slater, G., & Burke, L.M. (2017). Acute-weight-loss strategies for combat sports and applications to Olympic success. *International Journal of Sports Physiology and Performance, 12*(2), 142–151. PubMed ID: 27347784 doi:10.1123/ijspp.2016-0211

Riazi, S., Kraeva, N., & Hopkins, P.M. (2018). Malignant hyperthermia in the post-genomics era: New perspectives on an old concept. *Anesthesiology, 128*(1), 168–180. PubMed ID: 28902675 doi:10.1097/ALN.0000000000001878

Thompson, A.A. (2013). Sickle cell trait testing and athletic participation: A solution in search of a problem? *Hematology. American Society of Hematology. Education Program, 2013*, 632–637. PubMed ID: 24319243 doi:10.1182/asheducation-2013.1.632

Ward, M.M. (1988). Factors predictive of acute renal failure in rhabdomyolysis. *Archives of Internal Medicine, 148*(7), 1553–1557. PubMed ID: 3382301 doi:10.1001/archinte.1988.00380070059015

Downloaded by t_lambrinides@yahoo.com on 09/18/18, Volume ${article.issue.volume}, Article Number ${article.issue.issue}